Disease and Diagnosis

Dis Diagn. 2022; 11(1):36-38

10.34172/ddj.2022.08

Case Report

Coronavirus Disease 19 with Spontaneous Pneumomediastinum: A Report of Three Cases

Mehdi Hassani Azad[1], HamidReza Samimagham[2], Ehsan Ramezanian Nick[2], Mahdis Marashi[2], Dariush Hooshyar[3], Ali Bazram[2], Mitra KazemiJahromi[2*]

[1]Infectious and Tropical Diseases Research Center, Hormozgan Health Institute, Hormozgan University of Medical Sciences, Bandar Abbas, Iran
[2]Clinical Research Development Center, Shahid Mohammadi Hospital, Hormozgan University of Medical Sciences, Bandar Abbas, Iran
[3]Student Research Committee, Faculty of Medicine, Hormozgan University of Medical Sciences, Bandar Abbas, Iran

Abstract
Background: Coronavirus disease 19 (COVID-19) can cause many radiological manifestations on chest computed tomography (CT) scans. However, the occurrence of pneumomediastinum is rare in these patients. Accordingly, this study represents the rare cases encountered during the COVID-19 epidemic.
Case Presentation:: This study focuses on describing three patients who attended our medical center during the COVID-19 epidemic showing pneumomediastinum on chest CT scans. Patients' COVID-19 was confirmed after positive polymerase chain reaction tests. Finally, two of them were expired despite the efforts of the medical team.
Conclusion: Overall, the results of this study suggest the occurrence of pneumomediastinum on the CT scans of patients as a possible finding of COVID-19.
Keywords: COVID-19, Pneumomediastinum, Chest CT scan

***Correspondence to**
Mitra KazemiJahromi, Clinical Research Development Center, Shahid Mohammadi Hospital, Hormozgan University of Medical Sciences, Bandar Abbas, Iran
Tel: +00989177912820, Email: mitra.kazemijahromi@gmail.com

Received: December 14, 2020, Accepted: April 26, 2021, ePublished: January 1, 2022

Introduction

Following the spread of the new coronavirus pneumonia caused by severe acute respiratory syndrome coronavirus-2 (SARS-Cov-2) and its epidemic in late 2019, the World Health Organization named it coronavirus disease 2019 (COVID-19) and declared a pandemic in March 2020 (1,2). COVID-19 can lead to several radiological manifestations on the patient's chest computed tomography (CT) scan if it involves the lungs (3). Spontaneous pneumomediastinum is an unusual condition in viral pneumonia (3) and is commonly observed in mechanically ventilated patients and diseases such as infections, chronic pulmonary diseases, and asthma. Nonetheless, few cases have so far been announced regarding COVID-19 pneumomediastinum (4,5). Accordingly, this study reported three COVID-19 cases developing pneumomediastinum.

Case 1

A 34-year-old male patient with no underlying diseases presented with shortness of breath and no other symptoms from the day before admission. O_2 saturation was 94% and all physical examinations were normal. The patient's COVID-19 polymerase chain reaction (PCR) test was positive.

Pneumomediastinum was observed in the chest CT scan (Figure 1a), and lab tests were white blood cell count (WBC) of 17400 (m/mm^3), lymphocyte count of 14.8%, and *lactate dehydrogenase* (LDH) of 1454U/L. The patient was discharged after one week with improvements in his general condition and radiological presentation while he returned after 3 days with severe dyspnea with an O_2 saturation of 86%. Although the patient's pneumomediastinum had improved (Figure 1b), he expired 24 hours later.

Case 2

The patient was a 66-year-old man with no underlying diseases who presented to the hospital following shortness of breath several previous days. He was admitted due to pneumomediastinum in the chest CT scan and the likelihood of COVID-19 (Figure 2). The patient's COVID-19 PCR test was positive, and lab test results on admission were WBC count of 7600 (m/mm^3),

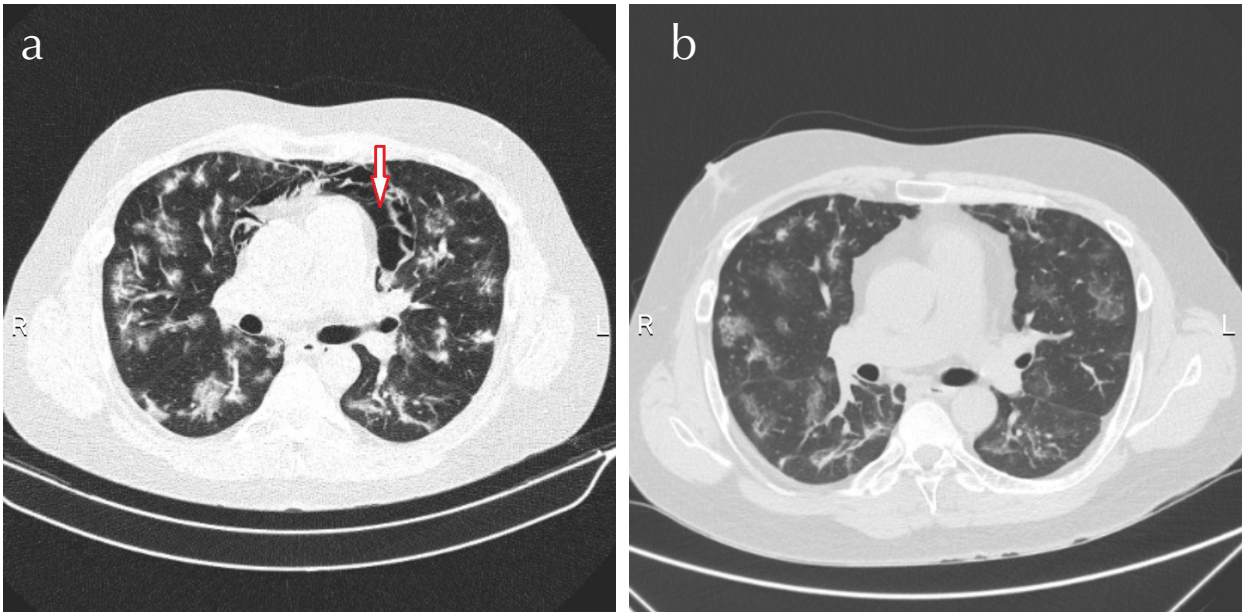

Figure 1. (a) Pneumomediastinum in the chest CT scan, (b) The patient's pneumomediastinum improved

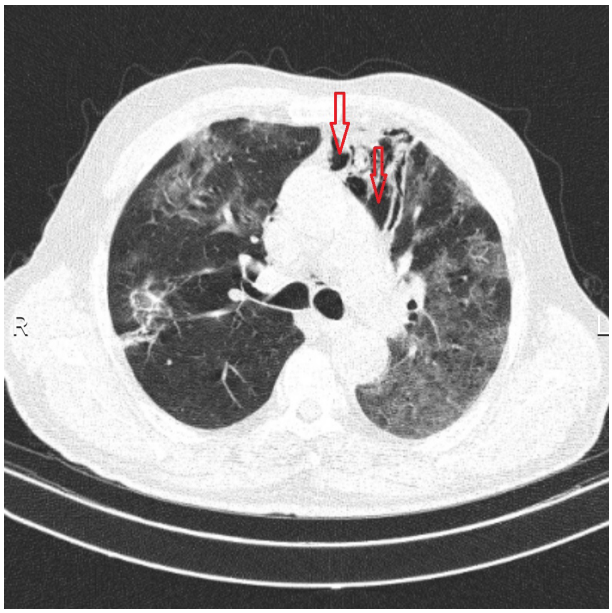

Figure 2. Pneumomediastinum in the chest CT scan and the likelihood of COVID-19.

lymphocyte count of 15%, and LDH of 399 U/L. He was discharged due to improvements in shortness of breath and good O_2 saturation (97%), as well as improvements in radiological and clinical manifestations.

Case 3

The patient was a 28-year-old woman with hypertension and valvular heart disease who presented with complaints of shortness of breath, fever, dry cough, and myalgia from a few days before the visit and was admitted due to the radiological evidence of COVID-19. The patient's COVID-19 PCR test was positive. During admission, the patient developed rising creatinine and underwent dialysis, and then was transferred to the intensive care unit (ICU) owing to worsening of respiratory distress and drop of O_2 saturation. The new chest CT scan, which was performed in the ICU revealed that the patient had developed pneumomediastinum (Figure 3). Lab tests on admission were WBC count of 17 200 (m/mm^3), lymphocyte count of 8.3%, LDH of 400 U/L, and creatinine (Cr) of 3.9 mg/dL. During hospitalization, WBC count, lymphocyte, LDH, and Cr were 36 300 (m/mm^3), 2.7%, 858U/L, and 6.5 mg/dL, respectively.

Due to the further drop of O_2 saturation down to 70% and respiratory distress, the patient was intubated and unfortunately, expired 3 days later.

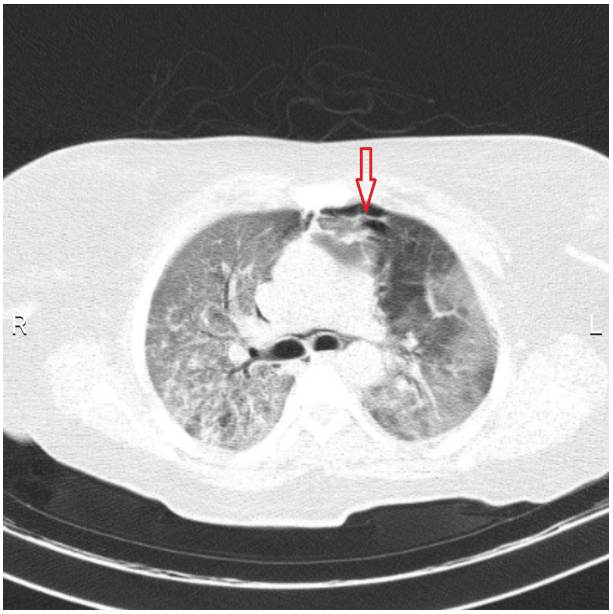

Figure 3. Pneumomediastinum in the chest CT scan.

Discussion

Numerous radiological manifestations have been reported on the chest CT scan since the outbreak of COVID-19, including multifocal bilateral peripheral ground-glass opacities, subsegmental patchy consolidation with subpleural location, predominant involvement of posterior segments, and lower lung lobes, and the like. Nevertheless, reports of pneumomediastinum have been scarce in recent studies (4,5).

As it is known, the pressure gradient between alveoli and pulmonary interstitium can lead to alveolar rupture, causing spontaneous pneumomediastinum (6). In COVID-19 cases, this can be described by SARS-Cov-2 activity that can damage the alveolar membrane (7,8).

To date, few cases of pneumomediastinum in COVID-19 patients have been reported that are not caused by ventilation (4,5). However, some cases have resulted in a pneumothorax (9). Although pneumomediastinum usually resolves spontaneously, as a complication of COVID-19, it can indicate the exacerbation of the disease (10).

Conclusion

The occurrence of pneumomediastinum is rare although it is a possible finding and thus should be considered in COVID-19 patients' chest CT scans.

Acknowledgments

We are sincerely thankful to the Clinical Research Development Center of Shahid Mohammadi Hospital for supporting this study.

Authors' Contribution

MKJ, HS, and MH supervised the entire study, and other authors participated in the treatment, data collection, and manuscript preparation.

Conflict of Interest Disclosures

The authors declare that they have no conflict of interests.

Ethical Statement

This study was approved by the Research Ethics Committee of Hormozgan University of Medical Sciences (IR.HUMS.REC.1399.228).

Informed Consent

The identifiable information of none of the patients was disclosed in this study.

References

1. Cucinotta D, Vanelli M. WHO declares COVID-19 a pandemic. Acta Biomed. 2020;91(1):157-60. doi: 10.23750/abm.v91i1.9397.
2. Samimagham HR, Seddighi K, Daryanavard A, Kazemi Jahromi M. Recurrence of COVID-19 Infection. Shiraz E Med J. 2021;22(8):e110656. doi: 10.5812/semj.110656.
3. Samimagham HR, Kazemi Jahromi M, Kazemi Jahromi L. COVID-19 with pneumomediastinum and emphysema, a case report. Shiraz E Med J. 2020;21(12):e109424. doi: 10.5812/semj.109424.
4. Volpi S, Ali JM, Suleman A, Ahmed RN. Pneumomediastinum in COVID-19 patients: a case series of a rare complication. European Journal of Cardio-Thoracic Surgery. 2020 Sep;58(3):646-7. doi: 10.1093/ejcts/ezaa222.
5. Mohan V, Tauseen RA. Spontaneous pneumomediastinum in COVID-19. BMJ Case Rep. 2020;13(5):e236519. doi: 10.1136/bcr-2020-236519.
6. Macia I, Moya J, Ramos R, Morera R, Escobar I, Saumench J, et al. Spontaneous pneumomediastinum: 41 cases. Eur J Cardiothorac Surg. 2007;31(6):1110-4. doi: 10.1016/j.ejcts.2007.03.008.
7. Kolani S, Houari N, Haloua M, Alaoui Lamrani Y, Boubbou M, Serraj M, et al. Spontaneous pneumomediastinum occurring in the SARS-COV-2 infection. IDCases. 2020;21:e00806. doi: 10.1016/j.idcr.2020.e00806.
8. Gralinski LE, Baric RS. Molecular pathology of emerging coronavirus infections. J Pathol. 2015;235(2):185-95. doi: 10.1002/path.4454.
9. Sun R, Liu H, Wang X. Mediastinal emphysema, giant bulla, and pneumothorax developed during the course of COVID-19 pneumonia. Korean J Radiol. 2020;21(5):541-4. doi: 10.3348/kjr.2020.0180.
10. Zhou C, Gao C, Xie Y, Xu M. COVID-19 with spontaneous pneumomediastinum. Lancet Infect Dis. 2020;20(4):510. doi: 10.1016/s1473-3099(20)30156-0